

Original Article

The Neuroanatomic Basis of the Acupuncture Principal Meridians

Peter T. Dorsher, MD, MSc

From the Department of Physical Medicine and Rehabilitation,
Mayo Clinic, Jacksonville, FL.

Address reprint requests to Peter T. Dorsher, MD, MSc, Mayo
Clinic, 4500 San Pablo Road, Jacksonville, FL 32224.

E-mail: dorsher.peter@mayo.edu

Conflict of Interest: none

Text word count (including text, references, table captions, and legends):

2912

Abstract word count: 150

No. of tables: 1

No. of figures: 4

Running title: Neuroanatomic Basis of Meridians

©2009 Mayo Foundation for Medical Education and Research

Abstract

Acupuncture involves treating illness by inserting needles at specified body locations (acupoints). The Principal meridians are pathways that join acupoints with related physiologic effects. Despite nearly 5000 years of continuous clinical study, an accepted anatomic or physiologic basis for acupuncture's clinical effects has remained elusive. Some acupoints overlie peripheral nerves, and fMRI studies demonstrate that acupoints have specific effects on central nervous system processing. Traditional Chinese Medicine (TCM) founders described the body's viscera based on anatomic dissections yet not a discrete nervous system. By applying computer graphics and virtual human imaging techniques to human developmental neuroanatomy, this paradox may potentially be explained: acupuncture Principal meridians likely are TCM's representation of the nervous system. This neuroanatomic model of the Principal meridians is consistent with acupuncture's known neurophysiologic effects, and may allow 5 millennia of accumulated TCM observations regarding human health and illness to be understood in modern anatomic and physiologic terms.

Introduction

Acupuncture is part of the most enduring system for diagnosing and treating human illness, namely, Traditional Chinese Medicine (TCM). Acupuncture originated nearly 5,000 years ago, and its tenets were first compiled in the *Nei Jing* treatise about 200 BC.¹ In the past decade, double-blinded, placebo-controlled studies and evidence-based reviews have documented acupuncture's efficacy for treating nausea and vomiting, dental pain, migraines, and neck and low back pain.²⁻⁷ The accumulated scientific evidence is such that the United Kingdom governmental health care guidelines for chronic low back pain now include acupuncture as a recognized effective treatment,⁸ and the recent American Pain Society guidelines for treatment of back pain elevated use of acupuncture for treating chronic back pain over injection therapies and surgery.⁹

Other civilizations independently discovered illness treatments similar to acupuncture. Ötzi, the 5,200-year-old "Iceman" found in the Tyrol Alps, has tattoo marks on his knee and ankle (near acupoints LR-8 and BL-60, respectively) as well as his back postulated to represent acupuncture-like treatment points for sciatica.¹⁰ Imhotep, the "father of medicine" who served as physician to the Egyptian pharaohs about 3000 BC, is the probable source of medical diagnosis and treatments described in the Ebers and Smith papyri (17th century BC), which include the concept of "metu", channels arising from the heart that circulate blood, air, and other bodily substances throughout the body and which manifest pain or illness if obstructed (analogous to TCM meridian physiology).¹¹ Mayan healers (termed

curanderos) used *jup* and *tok* needling techniques to “to move the stagnant blood and air”,¹² analogous to moving stagnant blood and *qi* (energy) with needling in TCM. Many body treatment points described by curanderos are at the same anatomic sites and have the same clinical indications as those described by the TCM tradition.¹² These four healing traditions though separated by differing millennia, languages, and continents described remarkably similar concepts of treating human illness, which suggests all these traditions may be describing a common underlying principle of human anatomy or physiology.

One of the greatest mysteries of TCM is that it describes all the major organs of the human body, but it has no representation of the nervous system. The lack of a demonstrable anatomic substrate for acupuncture points and the meridians on which they exist has hindered scientific acceptance of acupuncture. The ancient Chinese had extensive anatomic knowledge based on dissections of executed criminals,¹³ so it is improbable that the nervous system was not studied during these autopsies. An analysis of human developmental anatomy using computer graphics and virtual human imaging techniques may explain this paradox: Acupuncture meridians, previously thought to be only conceptual pathways that link acupuncture points with related clinical effects, are TCM’s representation of the nervous system.

The purpose of this paper is to describe anatomic and physiologic evidence that the acupuncture meridians follow the distributions of the peripheral nerves they approximate, and thus likely represent TCM’s representation of the human nervous system.

Neuroembryogenesis of Meridians in the Extremities

During the fourth to sixth weeks after conception, embryonic arm and leg buds form as linear structures, with the palms of the hands and soles of the feet facing each other.¹⁴ Joints develop in the seventh week, and the limbs subsequently flex and rotate to bring them into their birth positions.¹⁴

If adult limbs with their known dermatome and peripheral nerve distributions^{15,16} are placed in their sixth-week fetal positions,¹⁴ several important anatomic relationships develop (Figure 1). As shown on the left side of Figure 1, except for the anterior thigh and calf regions, the dermatomes approximate linear structures. The myotomes also straighten and underlie their corresponding dermatomes. For example, the triceps and extensor digitorum muscles (both C7 innervated) underlie the C7 dermatome. Figure 1 also demonstrates that the extremity peripheral nerves approximate straight lines that cross their appropriate dermatomes and myotomes. As examples, the ulnar nerve (C8-T1 innervated) traverses those dermatomes/myotomes in the arms; and the femoral nerve and its saphenous nerve branch (L2-4 innervated) traverse those dermatomes/myotomes in the legs.

The right side of Figure 1 shows that the distributions of the acupuncture Principal meridians and those of the peripheral nerves in the extremities are almost completely identical. As examples, the Lung meridian mirrors distribution of the musculocutaneous nerve and its lateral antebrachial cutaneous nerve branch in the arms; and the Bladder meridian mirrors distribution of the tibial branch of the sciatic nerve and its lateral plantar nerve branch in the legs. Peripheral nerves are accompanied by

arteries, whose walls contain rich sympathetic autonomic nervous system innervation. Moreover, about 20 % (or more) of peripheral nerve axons are sympathetic autonomic fibers.¹⁷ This arterial and peripheral nerve sympathetic innervation serves to provide parallel autonomic innervation along the acupuncture meridians' distributions.

In summary, placing the adult body in its sixth-week developmental position causes the extremities' dermatomes, myotomes, vasculature, and peripheral nerves to become largely linear structures. The distributions of the acupuncture Principal meridians in the extremities mirror those of the extremities' neurovascular bundles. These anatomic relationships can be independently confirmed with virtual human imaging techniques,¹⁸ as outlined in the supporting material.

Neuroembryogenesis of Meridians in the Trunk

In contrast to the linear development of embryonic limb innervation that leads to linear meridian organization in the limbs, the trunk is segmentally innervated in a band-like distribution (Figure 1). This derives from the lateral folding of the embryo about 3 weeks after conception that forms the pelvic, abdominal, and chest cavities (Figure 2).¹⁴ This folding causes the trunk acupuncture meridians to be organized in a segmental manner, coursing perpendicular to branches of the spinal nerves. These trunk meridians connect corresponding branches of the dorsal and ventral rami of the spinal nerves.

As shown in the transverse view in Figure 3, the medial branches of the dorsal rami of the spinal nerves innervate the interspinous ligaments over which the Governing Vessel meridian courses and the inner Bladder meridian, which courses about 3 cm from the midline. The musculoskeletal

effects described for inner Bladder meridian acupoints teleologically follow because the dorsal rami nerve branches that innervate them also innervate the numerous deep spinal muscles that control spine motion. The lateral branches of the dorsal rami of the spinal nerves innervate the outer Bladder meridian, which courses about 6 cm from the midline.

The transverse view in Figure 3 also demonstrates that the medial branches of the anterior cutaneous branches of the anterior rami of the spinal nerves innervate the Conception Vessel and Kidney meridians. As demonstrated in the frontal view in Figure 3, the anterior cutaneous branches of the spinal nerves below the thorax penetrate the abdominal wall fascia near the midline; while in the chest region, these branches penetrate the chest wall fascia more laterally. The course of the Kidney meridian as it ascends from the abdominal to the chest region mirrors this lateral anatomic shift of the anterior cutaneous branches of the spinal nerves.

The lateral branches of the anterior cutaneous nerves innervate the Stomach meridian. The Spleen meridian courses along the interfaces of the anterior branches of the lateral cutaneous branches of the spinal nerves with the lateral branches of their anterior cutaneous nerves. Analogous to the Kidney meridian, the described lateral shift of the Spleen meridian in the thorax follows the lateral anatomic shift of the interfaces of the anterior and lateral cutaneous branches of the spinal nerves there. Except for GB-24, Gallbladder acupuncture points on the trunk are proximate to where the lateral cutaneous branches of the spinal nerves penetrate the trunk fascia. The 2 trunk Liver acupoints (LR-13 and LR-14) are located proximate to anterior branches of lateral cutaneous branches of spinal nerves.

Neuroembryogenesis of Meridians in the Head and Neck

The embryologic development of the head and neck differs from that of the trunk and limbs but provides the neuroanatomic basis for the acupuncture meridians there. The posterior neck, scalp, eyes, ears, nose, and philtrum derive from the ectodermal layer as the rostral longitudinal fold of the embryo during the third to eighth weeks (Figure 2) brings the prochordal plate (future mouth) to the anterior body surface.¹⁴ Simultaneously, the branchial arches meet ventrally in the midline to form the anterior neck, jaw, and cheeks.¹⁴

Figure 4 demonstrates the relationship of the skull foramina (where cranial nerves exit) to the acupuncture Principal meridians there, with the Bladder meridian neuroanatomy shown. The frontal view documents that these foramina are arranged linearly and align precisely with the Principal meridians there.

Anatomic references^{15,16} document that extensive anastomoses occur between adjacent peripheral and/or cranial nerves in the head and neck region to provide the anatomic basis for the meridians there. For example, in Figure 4, the frontal view demonstrates that the Bladder meridian courses over the infratrochlear and supratrochlear nerves. Clemente¹⁶ documents that the supratrochlear and greater occipital nerves anastomose near the vertex. The lateral view in Figure 4 demonstrates that the Bladder meridian in the posterior head and neck courses over the greater occipital nerve. The distributions of other Principal meridians in the head and neck region can likewise be shown to derive from the anastomoses of cervical and/or cranial nerves (see supporting online material).

Physiologic Evidence of the Meridians' Neuroanatomic Basis

A second, independent line of physiologic evidence that supports the neuroanatomic basis of acupuncture in the trunk derives from the overlap of Eastern, Western, and osteopathic physiology. The *Shu* acupuncture points are used in TCM to directly influence organ function.¹³ The Table demonstrates that, except for those of the Large Intestine and Small Intestine, *Shu* points' anatomic locations overlap the known segmental sympathetic nervous system innervation of their associated organs and the spinal levels that osteopathic manipulations are performed to influence those organs' functions.^{19,20}

At least 2 contemporary medical devices have re-discovered the somatovisceral effects of acupuncture points, offering further physiologic evidence that the acupuncture meridians correspond to the peripheral nervous system. InterStim (Medtronic Inc, Minneapolis, Minnesota) is an implanted S2 sacral nerve root stimulator used to treat bladder detrusor instability. For millennia, acupuncturists have inserted needles through the S2 foramen at Bladder acupoint BL-32 to treat “painful urinary dysfunction” and “facilitate urination”.¹³ A posterior tibial nerve stimulator (Urgent PC; Uroplasty Inc, Minnetonka, Minnesota) is also used to treat bladder urge incontinence. This device stimulates the tibial nerve above the medial malleolus near Kidney acupoint KI-7, which is described to treat bladder dysfunction by “opening and regulating the water passages”.¹³

Discussion

Embryologic and anatomic analysis using virtual human software¹⁸ suggests that neurovascular bundles of the head, trunk, and extremities are the anatomic basis of the acupuncture meridians. This

elevates the meridians from being merely conceptual links between acupuncture points with related physiologic functions to being anatomic pathways in the body. This would also explain why Traditional Chinese Medicine physiology never described a discrete nervous system, as the meridians are its representation of the neurovascular system. The *Nei Jing*'s 2,200-year-old statement that blood and *qi* (energy) flow through the meridians¹³ would then literally be true.

Physiologic evidence corroborates this neuroanatomic basis of the meridians. Organ segmental autonomic nervous system innervation strongly corresponds to the spinal levels where the acupuncture *Shu* points¹³ are inserted to influence those organs' function and where osteopathic spine manipulation is performed to influence organ function.^{19,20} Commercial nerve stimulators used for treating urinary urge incontinence stimulate peripheral nerves at locations that acupuncturists have used for thousands of years to treat incontinence (“open and regulate the water passages”).

This neuroanatomic model is consistent with acupuncture's known neurophysiologic effects. The *deqi* sensation sought during needling of acupoints is a sensory phenomenon that likely includes both large and small diameter afferent fibers.²¹ There are multiple fMRI studies now that demonstrate acupuncture ultimately has its effects in the pre-frontal neocortical areas of the brain as well as paleocortical structures including anterior cingulate gyrus, thalamus, amygdale, and other portions of the limbic system.²²⁻²⁴ Acupuncture analgesia can be reversed by naloxone,²⁵ indicating central nervous system endorphins are involved in acupuncture's pain-relieving effects.

The acupuncture tradition provides nearly 5,000 years of clinical experience in using the body's endogenous mechanisms both to treat but

also to prevent illness. The neuroanatomic basis for acupuncture's effects demonstrated in this treatise can serve as a template to translate thousands of years of clinical observations of the body's somatovisceral and viscerosomatic reflexes into modern anatomic and physiologic terms. These data could then be used to develop novel, cost-effective treatments that ease human suffering, increase health care access, and reduce requirements for prescription medication use. New technological developments, including acupuncture "laser needles",²⁶ offer the potential for noninvasive, non-painful disease prevention and treatment. Recent World Health Organization recommendations to expand the worldwide use of acupuncture and other traditional medicine practices reflect the expanding evidence of acupuncture's efficacy, safety, and cost-efficiency.²⁷ This neuroanatomic model should accelerate acupuncture research and integration into health care practice.

Acknowledgment

Editing, proofreading, and reference verification were provided by the Section of Scientific Publications, Mayo Clinic.

References

1. Eckman, P. *In the footsteps of the yellow emperor: tracing the history of traditional acupuncture. 1st ed.* (Cypress Book Company, San Francisco, California, 1996).
2. Ernst, E. Acupuncture: what does the most reliable evidence tell us? *J. Pain Symptom Manage.* **37**, 709-714 (2009).
3. Acupuncture. *NIH Consensus Statement.* **15**, 1-34 (1997).
4. Herman, P.M., Craig, B.M. & Caspi, O. Is complementary and alternative medicine (CAM) cost-effective? A systematic review. *BMC Complement. Altern. Med.* **5**, 11 (2005).
5. Trinh, K. *et al.* Acupuncture for neck disorders. *Spine.* **32**, 236-243 (2007).
6. van Tulder, M.W., Furlan, A.D. & Gagnier, J.J. Complementary and alternative therapies for low back pain. *Best Pract. Res. Clin. Rheumatol.* **19**, 639-654 (2005).
7. Witt, C.M., Brinkhaus, B. & Willich, S.N. [Acupuncture. Clinical studies on efficacy and effectiveness in patients with chronic pain in German]. *Bundesgesundheitsblatt Gesundheitsforschung Gesundheitsschutz.* **49**, 736-742 (2006).
8. Ratcliffe, J., Thomas, K.J., MacPherson, H. & Brazier, J. A randomised controlled trial of acupuncture care for persistent low back pain: cost effectiveness analysis. *BMJ.* **333**, 611-612 (2006).
9. Chou, R. *et al.* Interventional therapies, surgery, and interdisciplinary rehabilitation for low back pain: an evidence-based clinical practice guideline from the American Pain Society. *Spine.* **34**, 1066-1077 (2009).

10. Dorfer, L. *et al.* A medical report from the Stone Age? *Lancet*. **354**, 1023-1025 (1999).
11. Nunn, J.F. *Ancient Egyptian medicine*. (British Museum Press, London, United Kingdom, 1996).
12. Garcia, H., Sierra, A. & Balam, G. *Wind in the blood: Mayan healing and Chinese medicine*. (North Atlantic Books, Berkeley, California, 1999).
13. O'Connor, J. & Bensky, D. editors and translators. *Acupuncture: a comprehensive text*. (Eastland Press, Chicago, Illinois, 1981).
14. Moore, K.L. & Persaud, T.V.N. *Before we are born: essentials of embryology and birth defects*. 4th ed. (Saunders Publishing, Philadelphia, Pennsylvania, 1993).
15. Netter, F.H. *Atlas of human anatomy*. (Ciba-Geigy, Summit, New Jersey, 1989).
16. Clemente, C.D. *Anatomy: a regional atlas of the human body*. 2nd ed. (Urban & Schwarzenberg, Baltimore, Maryland, 1981).
17. Ko, H.Y. *et al.* Unmyelinated fibers in human spinal ventral roots: C4 to S2. *Spinal Cord*. **47**, 286-289, 2009.
18. Dorsher, P.T., Cummings, M. *Anatomy for acupuncture [DVD-ROM]*. (Primal Pictures Limited, London, United Kingdom, 2007).
19. Bonica, J.J. Autonomic innervation of the viscera in relation to nerve block. *Anesthesiology*. **29**, 793-813 (1968).
20. Beal, M.C. Viscerosomatic reflexes: a review. *J. Am. Osteopath. Assoc.* **85**, 786-801 (1985).
21. Hui, K.K. *et al.* Characterization of the "deqi" response in acupuncture. *BMC Complement. Altern. Med.* **7**, 33 (2007).

22. Cho, Z.H. *et al.* fMRI neurophysiological evidence of acupuncture mechanisms. *Med. Acup.* **14**, 16-22 (2002).
23. Cho, Z.H. *et al.* New findings of the correlation between acupoints and corresponding brain cortices using functional MRI. *Proc. Natl. Acad. Sci. USA.* **95**, 2670-2673 (1998).
24. Hui, K.K. *et al.*: Functional MRI evidence that acupuncture modulates the limbic system and subcortical gray structures of the human brain. *Hum. Brain Mapp.* **9**, 13-25 (2000).
25. Pomerantz, B. & Chiu, D. Naloxone blockade of acupuncture analgesia: endorphin implicated. *Life Sci.* **19**, 1757-1762 (1976).
26. Weber, M., Fussganger-May, T. & Wolf, T. Needles of light: a new therapeutic approach. *Med. Acup.* **19**, 141-150 (2007).
27. World Health Organization. *Traditional Medicine.* **13**, 160-167 (1998). Available from <http://www.wpro.who.int/NR/rdonlyres/8D38FACA-F0B9-4F99-A699-FE663F9361EC/0/chapter13.pdf>

Table. Organ *Shu* Points, Osteopathic Levels, and Autonomic Innervation

Organ	<i>Shu</i> Point	Spinal Level	Sympathetic Segmental Innervation	Osteopathic Level
Lung	BL-13	T3	T2-T5 (T2-T7)	T3-T9
Pericardium	BL-14	T4	T1-T4 (T1-T5?)	C8, T1-T8?
Heart	BL-15	T5	T1-T4 (T1-T5)	C8, T1-T8
Liver	BL-18	T9	T7-T9 (T5-T10)	T6-T11
Gallbladder	BL-19	T10	T7-T10 (T5-T10)	T6-T11
Spleen	BL-20	T11	T6-T10 (T5-T11)	T7-T10
Stomach	BL-21	T12	T6-T10 (T5-T11)	T7-T10
Triple Energizer (? Adrenal)	BL-22	L1	Cortex T6-L2 Medulla T11-L1	
Kidney	BL-23	L2	T11-L1 (T10-L2)	T9-L2
Large Intestine	BL-25	L4	Proximal 2/3 T11-L1 (T6-L1) Distal 1/3 L1-L2 (T6-L2) (White, afferent S2-S4)	T9-L1
Small Intestine	BL-27	S1	T9-T11 (T6-T12)	T6-T11 duodenum & jejunum
Bladder	BL-28	S2	T11-L2 (white, afferent S2-S4) S2-S3 parasympathetic	

Legends

Figure 1. Adult dermatomes with peripheral nerves (left) and acupuncture meridians superimposed on peripheral nerves (right) in the extremities.

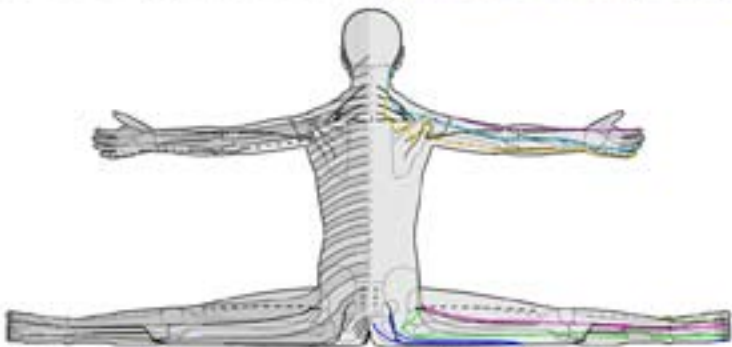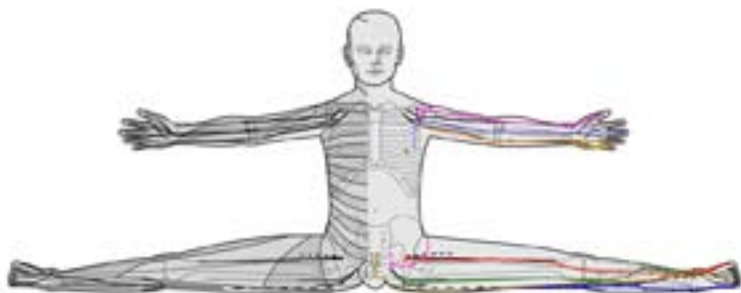Figure 2. Embryonic longitudinal (head/tail) and lateral folds at 3 weeks after conception.












Figure 3. Relationship of acupuncture meridians to branches of the segmental spinal nerves, transverse (left) and frontal (right) views. (Modified from Clemente.¹⁷ Used with permission).

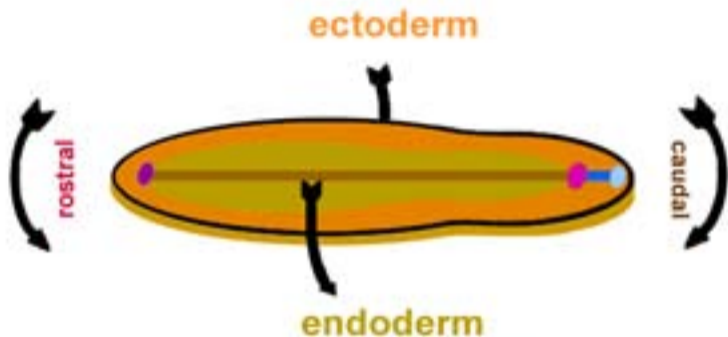
Figure 4. Relationships of skull foramen, cranial nerves, and principal acupuncture meridians in frontal (left) and lateral (right) views (trigeminal nerve V₁ branches in yellow hues: infratrochlear [light orange], supratrochlear [yellow], and supraorbital [orange] nerves; V₂ branches in red hues: zygomaticotemporal [red], zygomaticofacial [fuchsia], and infraorbital [maroon] nerves; and V₃ branches in purple hues: buccal [lavender] and mental [purple] nerves; greater occipital nerve [C2] shown in blue).

Table. Organ *Shu* Points, Osteopathic Levels, and Autonomic Innervation

Organ	<i>Shu</i> Point	Spinal Level	Sympathetic Segmental Innervation	Osteopathic Level
Lung	BL-13	T3	T2-T5 (T2-T7)	T3-T9
Pericardium	BL-14	T4	T1-T4 (T1-T5?)	C8, T1-T8?
Heart	BL-15	T5	T1-T4 (T1-T5)	C8, T1-T8
Liver	BL-18	T9	T7-T9 (T5-T10)	T6-T11
Gallbladder	BL-19	T10	T7-T10 (T5-T10)	T6-T11
Spleen	BL-20	T11	T6-T10 (T5-T11)	T7-T10
Stomach	BL-21	T12	T6-T10 (T5-T11)	T7-T10
Triple Energizer (? Adrenal)	BL-22	L1	Cortex T6-L2 Medulla T11-L1	
Kidney	BL-23	L2	T11-L1 (T10-L2)	T9-L2
Large Intestine	BL-25	L4	Proximal 2/3 T11-L1 (T6-L1) Distal 1/3 L1-L2 (T6-L2) (White, afferent S2-S4)	T9-L1
Small Intestine	BL-27	S1	T9-T11 (T6-T12)	T6-T11 duodenum & jejunum
Bladder	BL-28	S2	T11-L2 (white, afferent S2-S4) S2-S3 parasympathetic	



bladder	 governor vessel	large intestine	 master of heart	stomach	
conception vessel	 heart	 liver	 small intestine	triple energizer	
galbladder	 kidney	 lung	 spleen		



■ prochordal plate

■ notochordal process

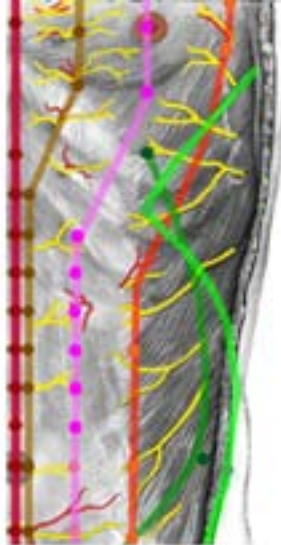
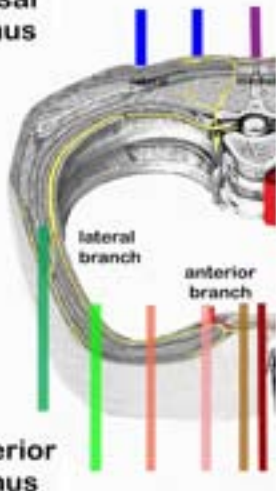
■ neural fold

■ primitive node

■ primitive streak

■ cloacal membrane

dorsal
ramus

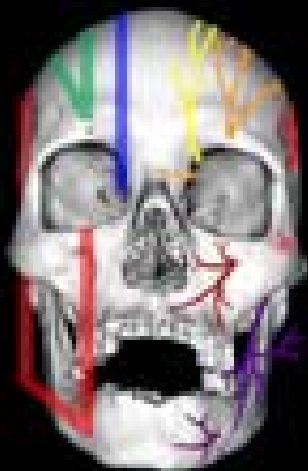

bladder
conception vessel
gallbladder

governor vessel
kidney
liver

spleen
stomach





bladder
meridian

galbladder
meridian

stomach
meridian

